

## Research Article

# Evaluation of the Effect of the Facial Nerve Monitoring in Mastoid Surgery

Abhishek Bhardwaj, Neeraj Narayan Mathur\*

Department of Otorhinolaryngology, Vardhmann Mahavir Medical College and Safdarjung Hospital, India

## \*Corresponding author

Neeraj Narayan Mathur, Department of Otorhinolaryngology, Vardhmann Mahavir Medical College and Safdarjung Hospital, 173 AGCR Enclave, Delhi, India- 110092, Tel: 91-98-111-096-37; Fax: 91-11-267-144-27; Email: drnmathur@gmail.com

Submitted: 07 April 2015

Accepted: 04 May 2015

Published: 06 May 2015

## Copyright

© 2015 Mathur et al.

## OPEN ACCESS

## Keywords

- Facial nerve
- Monitoring
- Intraoperative
- Mastoid
- Electric stimulation

## Abstract

**Objectives:** 1.To evaluate role of facial nerve monitoring in mastoid surgeries. 2. To define the cutoff limit for electrical dehiscence of facial nerve.

**Methodology:** 60 patients of chronic otitis media undergoing mastoid surgery were divided into 30 each for intra-operative facial nerve monitoring (group A) and those without monitoring (group B). Minimum level of current strength for stimulation of facial nerve was noted. Post operative facial nerve status and disease clearance was compared between two groups.

**Results:** In group A, 10 exhibited surgical dehiscence of facial nerve and responded to electrical stimulation of 0.5mA or less. Hence, we defined the facial nerves that responded to electrical stimulation of 0.5 mA or less with a constant, unipolar current with a frequency of 3 pulses/ second for 200  $\mu$ s as “electrically dehiscent”. Total “electrically dehiscent” cases were 16 (53.3%) Disease could not be cleared completely in 1 patient in group A and 3 in group B. Facial nerve integrity was maintained in all patients in group A but injured in 1 in group B.

**Conclusions:** Facial nerve monitor is a useful tool to be used in mastoid surgery as it reassures the surgeon when in doubt. All facial nerves which get stimulated with a current of 0.5mA or less can be taken as electrically dehiscent.

## INTRODUCTION

Facial nerve injury is a grave complication of otological surgery. During middle ear surgery and mastoid surgery, the facial nerve is vulnerable to injury because of its close proximity to the cochlea, oval window, stapes, lateral semicircular canal, and incus [1].

The problems generated by facial palsy are not just cosmetic. Patients may present with a spectrum of symptoms ranging from mild transient facial paralysis to complete permanent facial paralysis depending on the magnitude of injury. Loss of blink function and the ability to tear, if not treated properly, can create severe eye discomfort and even loss of vision. Other problems include oral incontinence (drooling), nasal valve collapse, and slurred speech. The importance of facial nerve monitors is borne out by the grave complications that can result from facial nerve injury during surgery. Historically, detection of facial nerve activity during surgery was possible by ingenious inventions such as suturing bells to the patients face and listening for a response [2]. Mechanical stimulation by a rotating burr or instrument touching the facial nerve would elicit facial contractions, thus warning the surgeon of impending facial nerve trauma [3].

One of the first facial nerve stimulators was the Montgomery/Lingemann nerve stimulator (Richards Co., Memphis, TN) [3] (Table 1). This unit required that the surgical assistant's hand be placed on the face to monitor facial contractions during stimulation of the facial nerve.

Monitor instructs the surgeon about proximity to the nerve as the strength of current required to stimulate the nerve increases in direct proportion to the distance from the nerve. It provides for stimulation of the nerve without actually coming in direct contact with it.

Needle electrodes placed in frontalis, orbicularis oculi

**Table 1:** Surgical dehiscence of the facial nerves according to location.

Location	Number (%)
Tympanic Segment only	14 (63.6)
Second Genu only	3 (13.6)
Mastoid Segment only	2 (9.1)
Tympanic Segment+ Second Genu	2 (9.1)
Tympanic Segment +Second Genu +Mastoid Segment	1 (4.5)

and oris detect EMG potentials generated in these muscles as a result of electrical or surgical stimulation of the facial nerve. EMG potentials are amplified and converted into an audible and visual graphical signal by the monitor. This warns the surgeon of impending proximity to the nerve. At the completion of surgery the electrical integrity of the nerve can be assessed by proximal stimulation (Figure 1). Short acting muscle relaxant is used to facilitate tracheal intubation on the premise that effect of the relaxant will have worn off by the time monitoring is required [4,5].

The aim of this study was to evaluate the role of facial nerve monitor in preservation of facial nerve integrity and its usefulness in complete clearance of disease in mastoid surgery. Study also aimed at finding the minimum level of current required for facial nerve stimulation and thus defining electrical dehiscence (Table 2).

### MATERIALS AND METHODS

The study was conducted in the department of Otorhinolaryngology, VMMC & Safdarjung hospital, New Delhi. Study included sixty patients of chronic otitis media undergoing mastoid surgery divided into two groups of 30 each. Group A included those with intra-operative facial nerve monitoring and Group B being those without monitoring. Group B included patients who underwent mastoid surgery before installation of the Nerve Monitor for mastoid surgery in the institute (Figure 2). A written informed consent was taken from all patients before surgery explaining the procedure involved possible outcomes and complications. Patients with any grade of facial paresis at the time of presentation were excluded. We used Neurosign 100 Nerve Monitor (The Magstim Co Ltd., Whitland, U.K.) for intraoperative facial nerve monitoring (Table 3).

Two separate channels of sterile disposable twisted triple electrodes were inserted ipsilaterally in orbicularis oculi and orbicularis oris muscles. We stimulated the facial nerve at its second genu, tympanic segment, and mastoid segment with a constant, unipolar current with a frequency of 3 pulses/ second

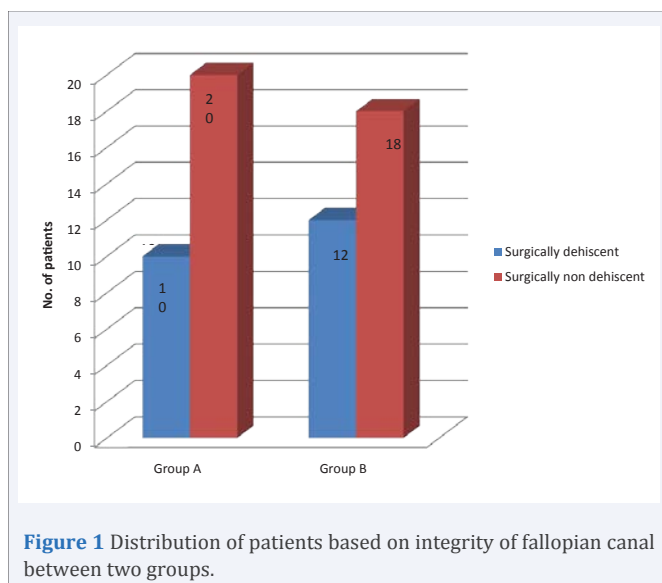


Figure 1 Distribution of patients based on integrity of fallopian canal between two groups.

Table 2: Minimum threshold of current for facial nerve stimulation.

Strength of current (mA)	Number of cases in patients with surgically dehiscent facial nerve group	Number of cases in patients with surgically non dehiscent facial nerve group
0.1	1	0
>0.1-<0.2	1	0
0.2	3	0
>0.2-<0.5	3	3
0.5	2	3
>0.5-<1	0	12
1	0	1
>1-<2	0	1

Abbreviations: mA – milli ampere

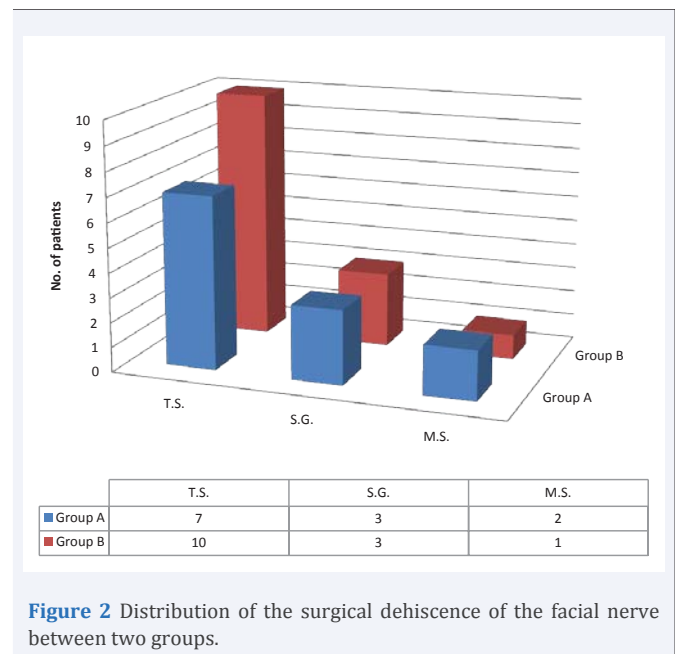


Figure 2 Distribution of the surgical dehiscence of the facial nerve between two groups.

for 200 μs using a disposable monopolar probe. Stimulation thresholds ranged from 0.05 mA to 2 mA with calibrations at 0.05 mA, 0.1 mA, 0.2 mA, 0.5 mA, 1 mA and 2 mA. EMG activity was recorded using acoustic and graphic signals. The instrument gives an audible interpretation of muscle activity, which is sensed by needle electrodes placed into the muscles supplied by facial nerve (Figure 3). The bargraph for each channel lights on stimulation of facial nerve showing the level of EMG activity. Each bargraph is calibrated from 30μV to 20mV peak-to-peak. With the electrodes correctly placed, no part of the bargraph lights unless the muscle is stimulated, either spontaneously or by the surgeon, either through manipulation or electrical stimulation of the nerve. The minimum intensity which elicited a response of ≥100 μV on at least 1 channel was defined as the threshold (Figure 4). Minimum level of current required to stimulate facial nerve in Tympanic segment, Second genu and Mastoid segment was assessed. Muscle relaxant was avoided during the surgical procedure (Table 4). Disease clearance was assessed in area close to facial nerve, sinus tympani and compared between two

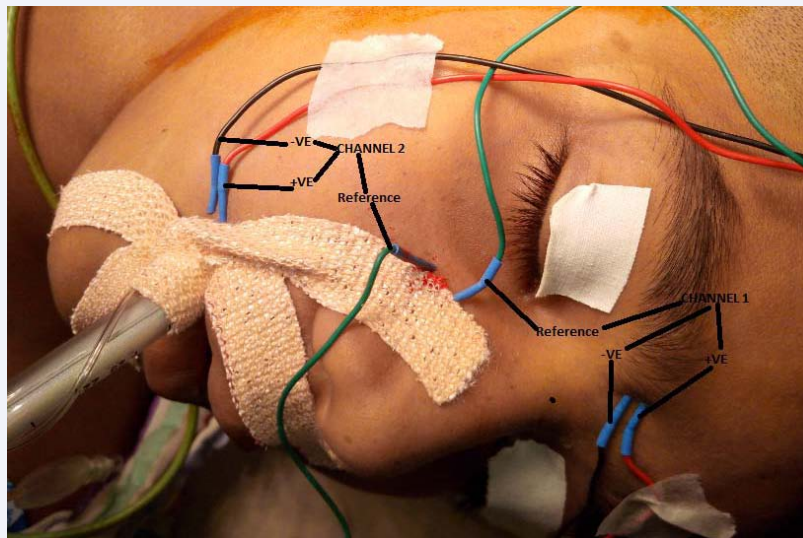


Figure 3 Showing position of electrodes.

Table 3: Distribution of cases based on minimum threshold of current for stimulation at T.S.

Surgical dehiscence	0.1 mA	>0.1-<0.2 mA	0.2 mA	>0.2-<0.5 mA	0.5 mA	>0.5-<1 mA	1 mA	>1-<2 mA
T.S. dehiscence	0	1	2	2	2	0	0	0
Other segment dehiscence but T.S. intact	0	1	0	1	0	1	0	0
Non dehiscent	0	0	0	3	3	12	1	1

Abbreviations: TS – Tympanic Segment

Table 4: Distribution of cases based on minimum threshold of current for stimulation at S.G.

Surgical dehiscence	0.1 mA	>0.1-<0.2 mA	0.2 mA	>0.2-<0.5 mA	0.5 mA	>0.5-<1 mA	1 mA	>1-<2 mA
S.G. dehiscence	1	1	0	1	0	0	0	0
Other segment dehiscence but S.G. intact	0	0	0	5	0	2	0	0
Non dehiscent	0	0	0	2	3	13	1	1

Abbreviations: SG – Second Genu

groups. Post operative facial nerve function was assessed based on House Brackmann classification for facial nerve integrity and compared.

## RESULTS

Mean age of patients was 19.6 years in group A and 24.8 years in group B. Out of 60 patients, bilateral ears were diseased in 16 (26.67%) patients, right ear in 17 (28.33%) and left ear in 27 (45%) patients. 57(95%) were for primary surgery and 3(5%) were for revision surgery.

Out of 60 patients, 22(37%) had surgical dehiscence of the facial nerve and 38 (63%) had intact fallopian canal.

The most common site of surgical dehiscence was tympanic segment, seen in 17 of 22 (77.3%) cases. Second genu was dehiscent in 6 (27.27%) and mastoid segment in 3 (13.6%) cases.

In group A, all surgically dehiscent facial nerves responded to electrical stimulation of 0.5 mA or less. Hence, we defined the facial nerves that responded to electrical stimulation of 0.5 mA or less with a constant, unipolar current with a frequency of 3 pulses/ second for 200  $\mu$ s as “electrically dehiscent”. All surgically dehiscent facial nerves also got included as electrically dehiscent. However, 6 were electrically dehiscent but surgically non dehiscent cases. Thus, total “electrically dehiscent” cases were 16 (53.3%).

In group A, out of 10 cases with surgically dehiscent facial nerve, 8 (80%) could be stimulated with a minimum threshold current of 0.2-0.5 mA and 2 (20%) with a minimum threshold current of <0.2 mA. Out of 20 cases with surgically non dehiscent facial nerve, 6 (30%) could be stimulated with a minimum threshold current of  $\leq$ 0.5 mA, 12 (60%) with a minimum threshold current of >0.5-<1 mA, and 2 (10%) with a minimum threshold current of 1-2 mA (Figure 5).

In group A, 2 out of 3 (75%) cases in which tympanic segment was intact but other segment was dehiscent could be stimulated at tympanic segment with current  $<0.5$  mA. Out of 20 cases with intact facial canal in all segments, only 3 (15%) could be stimulated at tympanic segment with current  $<0.5$  mA.

In group A, 5 out of 7 (71.4%) cases in which second genu was intact but some other segment dehiscent, could be stimulated at second genu with current  $<0.5$  mA. Out of 20 cases with intact facial canal in all segments, only 2 (10%) could be stimulated at second genu with current  $<0.5$  mA.

In group A, 6 out of 7 (85.7%) cases in which mastoid segment was intact but other segment dehiscent could be stimulated at mastoid segment with current  $\leq 0.5$  mA. Out of 12 cases with intact facial canal in all segments, only 2 (16.6%) could be stimulated at mastoid segment with current  $\leq 0.5$  mA.

Disease was present in area close to facial nerve in all 60 cases and was removed completely in 29 of 30 (96.67%) cases with facial nerve monitoring and 27 of 30 (90%) cases without facial nerve monitoring.

Post operative facial nerve integrity was maintained in all cases but one (Figure 6).

## DISCUSSION

Facial nerve injury is one of the most severe complications among temporal bone surgeries. It is increased when the normal anatomic landmarks of the temporal bone are altered [6,7]. Previous surgery, granulation tissue, and cholesteatoma can distort the normal anatomy and complicate the surgery [7,8]. It is very difficult for the surgeon to predict before surgery variations of the facial nerve, such as congenital bony dehiscence or abnormal course of the facial canal. Therefore, intraoperative facial nerve monitoring should be required for temporal surgeries (Table 5). However, the role of intraoperative facial nerve monitoring in middle ear and mastoid surgeries has not been well established [9,10].

In a study by Choung et al [11], surgical dehiscence was 43.0%. Li et al [12] found facial nerve dehiscence of 11.4% by microscope use during surgeries. Baxter [13] reported a dehiscence rate of 55% based on temporal bone histopathology. Sheehy et al [14] reported a surgical dehiscence of 44% including congenital dehiscence of 15% and cholesteatoma derived dehiscence of 17%. In our study, out of 60 patients, 22 (36.67%) had surgical dehiscence of facial nerve which is comparable to the study by Choung et al [11] and Sheehy et al [14]. Higher incidence of surgical dehiscence in a study by Baxter [13] can be attributed

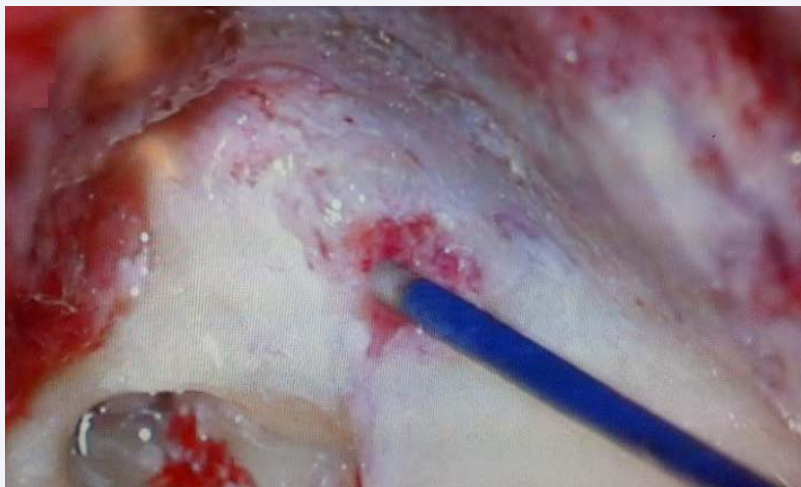

Figure 4 Showing stimulation of dehiscent tympanic segment.



Figure 5 Showing no signal on graph depicting correct fitting of electrodes.



**Figure 6** Showing positive response on monitor after stimulating the facial nerve.

**Table 5:** Distribution of cases based on minimum threshold of current for stimulation at Mastoid Segment (M.S.).

Surgical dehiscence	0.1 mA	>0.1-<0.2 mA	0.2 mA	>0.2-<0.5 mA	0.5 mA	>0.5-<1 mA	1 mA	>1-<2 mA
M.S. dehiscence	0	0	0	1	1	0	0	0
Other segment dehiscence but M.S. intact	0	0	1	2	3	1	0	0
Non dehiscent	0	0	0	0	2	7	3	0

**Abbreviations:** MS - Mastoid Segment

**Table 6:** Post operative facial nerve status in two groups.

	Post operative facial nerve integrity	
	Intact	Paresis
Group A	30	0
Group B	29	1

to dehiscence encountered on undersurface during temporal bone dissection which could not be detected during surgery.

The most common site of dehiscence was the tympanic segment, in 17 of 22 cases (77.27%) which was similar to Baxter's [13] (85%) and Choung et al [11] (90.7%) results suggesting that the tympanic segment of the facial nerve is the most risky portion and warrants more caution during manipulation of the facial nerve around the stapes.

All surgically dehiscent cases were stimulated at minimum threshold  $\leq 0.5\text{mA}$  with a constant, unipolar current with a frequency of 3 pulses/ second for 200  $\mu\text{s}$ . This result is consistent with the known fact that the response threshold of healthy nerves is about 0.1 to 0.5 mA [15]. This value was lower compared to the value of 0.7 mA in a study by Choung et al [11] in which facial nerve was stimulated by unipolar current with a frequency of 4 pulses/second for 100  $\mu\text{s}$ .

All surgically dehiscent facial nerves responded to electrical stimulation of 0.5 mA or less. In this study, electrical dehiscence was seen in 53.3% of total cases and 30% of surgically non dehiscent cases. In a study by Choung et al [11] electrical dehiscence was seen in 73% of total cases and in 52.6% of surgically non dehiscent cases. In a study by Noss et al [9], there

was a 13% incidence of surgical dehiscence and a 62% incidence of electrophysiological dehiscence. Electrical dehiscence in surgically non dehiscent cases may be due to very thin bony covering over the facial nerve or micro-dehiscence undetectable using microscope [11].

The disease in close relation to facial nerve could not be cleared in 4 cases; 1 with facial nerve monitoring and 3 without facial nerve monitoring. In the single case with facial nerve monitoring where the disease close to facial nerve could not be cleared had granulation tissue covering second genu of the facial nerve and also distal part of tympanic segment. Dehiscent second genu could be stimulated at 0.1 mA. Stimulation threshold over the granulation tissue was  $>0.1- <0.2$  mA. In this case the disease was left at second genu and distal part of tympanic segment because of the risk of facial nerve injury in the presence of very low stimulation thresholds. However, the facial nerve monitoring aided in the surgical decision making process and averted a potential injury to the facial nerve in other cases.

In 2 out of 3 cases done without facial nerve monitoring, the facial nerve was noted to be dehiscent under granulation tissue and hypertrophic mucosa at mastoid segment in first case and tympanic segment and second genu in a second case. To avoid

facial nerve injury, disease was left in the region of dehiscence of facial nerve (Table 6).

In 1 out of 3 cases without facial nerve monitoring with incomplete disease clearance, there was iatrogenic injury of the facial nerve. Facial nerve was dehiscence near processus cochleariformis in the tympanic segment and also at second genu with hypertrophic mucosa and granulation tissue overlying it, which made the identification of nerve difficult. In the process of delineating the facial nerve and clearing the granulations, second genu got accidentally injured. Repair with greater auricular nerve grafting was done and the nerve function recovered later.

The best means of preventing iatrogenic nerve damage is a keen knowledge of anatomy, coupled with meticulous surgical technique. At best, intraoperative monitoring acts as an aid but cannot compensate for poor technique, lack of experience or bad judgement.

## LIMITATIONS

Number of patients included in the study was less because of logistics in our institutional set up. In the group without facial nerve monitoring one patient developed facial palsy which is important considering the morbidity associated.

EMG tracing was not done and EMG activity was recorded by acoustic and graphical signals. But in order to avoid electrical artifacts, correct fitting of electrode was confirmed by impedance meter as well as absence of any positive signal or sound in absence of electrical stimulation and only those readings were taken into consideration which elicited a minimum response of 100µV.

## CONCLUSION

Facial nerve monitor does not seem to have a significant role in final outcome with regard to disease clearance or prevention of iatrogenic facial nerve injury. However, it is a useful tool to be used in mastoid surgery as it reassures the surgeon when in doubt. 0.5mA can be considered as a cut off value for defining electrical dehiscence. All facial nerves which get stimulated with a current of 0.5mA or less with a constant, unipolar current with a frequency of 3 pulses/ second for 200 µs can be taken as electrically dehiscence.

## REFERENCES

1. Proctor B. The anatomy of the facial nerve. *Otolaryngol Clin North Am.* 1991; 24: 479-504.
2. Williams JD, Lehman R. Bells against palsy. *Am J Otol.* 1988; 9: 81-82.
3. Silverstein H1, Rosenberg S. Intraoperative facial nerve monitoring. *Otolaryngol Clin North Am.* 1991; 24: 709-725.
4. Blair EA, Teeple E Jr, Sutherland RM, Shih T, Chen D. Effect of neuromuscular blockade on facial nerve monitoring. *Am J Otol.* 1994; 15: 161-167.
5. Colletti V, Fiorino FG, Policante Z, Bruni L. New perspectives in intraoperative facial nerve monitoring with antidromic potentials. *Am J Otol.* 1996; 17: 755-762.
6. Selesnick SH, Lynn-Macrae AG. The incidence of facial nerve dehiscence at surgery for cholesteatoma. *Otol Neurotol.* 2001; 22: 129-132.
7. Green JD Jr, Shelton C, Brackmann DE. Iatrogenic facial nerve injury during otologic surgery. *Laryngoscope.* 1994; 104: 922-926.
8. Green JD Jr, Shelton C, Brackmann DE. Surgical management of iatrogenic facial nerve injuries. *Otolaryngol Head Neck Surg.* 1994; 111: 606-610.
9. Noss RS, Lalwani AK, Yingling CD. Facial nerve monitoring in middle ear and mastoid surgery. *Laryngoscope.* 2001; 111: 831-836.
10. Greenberg JS, Manolidis S, Stewart MG, Kahn JB. Facial nerve monitoring in chronic ear surgery: US practice patterns. *Otolaryngol Head Neck Surg.* 2002; 126: 108-114.
11. Choung YH, Park K, Cho MJ, Choung PH, Shin YR, Kahng H. Systematic facial nerve monitoring in middle ear and mastoid surgeries: "surgical dehiscence" and "electrical dehiscence". *Otolaryngol Head Neck Surg.* 2006; 135: 872-876.
12. Li D, Cao Y. Facial canal dehiscence: a report of 1,465 stapes operations. *Ann Otol Rhinol Laryngol.* 1996; 105: 467-471.
13. Baxter A. Dehiscence of the Fallopian canal. An anatomical study. *J Laryngol Otol.* 1971; 85: 587-594.
14. Sheehy JL, Brackmann DE, Graham MD. Cholesteatoma surgery: residual and recurrent disease. A review of 1,024 cases. *Ann Otol Rhinol Laryngol.* 1977; 86: 451-462.
15. Yingling CD. Intraoperative monitoring of cranial nerves in neurotologic surgery. In: Cummings CW, Fredrickson JM, editors. *Otolaryngology- head and neck surgery.* 3rd ed. St. Louis: Mosby Year Book; 1993. p. 3351-55.

### Cite this article

Bhardwaj A, Mathur NN (2015) Evaluation of the Effect of the Facial Nerve Monitoring in Mastoid Surgery. *Ann Otolaryngol Rhinol* 2(4): 1032.